



Australian Government
Department of Health

COMMUNICABLE DISEASES INTELLIGENCE

2020 Volume 44
<https://doi.org/10.33321/cdi.2020.44.22>

Acute flaccid myelitis – has it gone unrecognised in Australian children?

Junchao Bao, Bruce Thorley, Elizabeth J Elliott, Peter McIntyre
and Philip N Britton

Communicable Diseases Intelligence

ISSN: 2209-6051 Online

This journal is indexed by Index Medicus and Medline.

Creative Commons Licence - Attribution-NonCommercial-NoDerivatives CC BY-NC-ND

© 2020 Commonwealth of Australia as represented by the Department of Health

This publication is licensed under a Creative Commons Attribution-Non-Commercial NoDerivatives 4.0 International Licence from <https://creativecommons.org/licenses/by-nc-nd/4.0/legalcode> (Licence). You must read and understand the Licence before using any material from this publication.

Restrictions

The Licence does not cover, and there is no permission given for, use of any of the following material found in this publication (if any):

- the Commonwealth Coat of Arms (by way of information, the terms under which the Coat of Arms may be used can be found at www.itsanhonour.gov.au);
- any logos (including the Department of Health's logo) and trademarks;
- any photographs and images;
- any signatures; and
- any material belonging to third parties.

Disclaimer

Opinions expressed in Communicable Diseases Intelligence are those of the authors and not necessarily those of the Australian Government Department of Health or the Communicable Diseases Network Australia. Data may be subject to revision.

Enquiries

Enquiries regarding any other use of this publication should be addressed to the Communication Branch, Department of Health, GPO Box 9848, Canberra ACT 2601, or via e-mail to: copyright@health.gov.au

Communicable Diseases Network Australia

Communicable Diseases Intelligence contributes to the work of the Communicable Diseases Network Australia.
<http://www.health.gov.au/cdna>



Communicable Diseases Intelligence (CDI) is a peer-reviewed scientific journal published by the Office of Health Protection, Department of Health. The journal aims to disseminate information on the epidemiology, surveillance, prevention and control of communicable diseases of relevance to Australia.

Editor

Cindy Toms

Deputy Editor

Simon Petrie

Design and Production

Kasra Yousefi

Editorial Advisory Board

David Durrheim,
Mark Ferson, John Kaldor,
Martyn Kirk and Linda Selvey

Website

<http://www.health.gov.au/cdi>

Contacts

Communicable Diseases Intelligence is produced by:
Health Protection Policy Branch
Office of Health Protection
Australian Government
Department of Health
GPO Box 9848, (MDP 6)
CANBERRA ACT 2601

Email:

cdi.editor@health.gov.au

Submit an Article

You are invited to submit your next communicable disease related article to the Communicable Diseases Intelligence (CDI) for consideration. More information regarding CDI can be found at:
<http://health.gov.au/cdi>.

Further enquiries should be directed to:
cdi.editor@health.gov.au.

Acute flaccid myelitis – has it gone unrecognised in Australian children?

Junchao Bao, Bruce Thorley, Elizabeth J Elliott, Peter McIntyre and Philip N Britton

Abstract

We have identified a previously unrecognised cluster of a newly recognised condition – acute flaccid myelitis (AFM) – among acute flaccid paralysis (AFP) cases identified by the Australian Paediatric Active Enhanced Disease Surveillance Network (PAEDS) 2007–2017. In the 12 months before and after detection of enterovirus D68 (EV-D68) from a single AFP case in April 2016, 24 of 97 notified cases of AFP were found to be clinically compatible with AFM; of these 24 cases, ten, clustered in early 2016, met magnetic resonance imaging (MRI) criteria for AFM. Detection of emerging enteroviruses requires collection of respiratory, cerebrospinal fluid and stool specimens, and should be routine practice for all AFP cases.

Keywords: Acute Flaccid Paralysis, Acute Flaccid Myelitis, Polio, Poliomyelitis, Enterovirus, EV-D68, AFP Surveillance

Introduction

Australia maintains acute flaccid paralysis (AFP) surveillance (Box 1) to comply with the World Health Organization (WHO) surveillance targets required to demonstrate adequate monitoring of paralytic poliomyelitis. AFP surveillance is coordinated jointly by the Australian Paediatric Surveillance Unit (APSU; www.apsu.org.au)¹ and the Paediatric Active Enhanced Disease Surveillance Network (PAEDS; www.paeds.edu.au)² in collaboration with the National Enterovirus Reference Laboratory, the Victorian Infectious Diseases Reference Laboratory (VIDRL). Recently, the importance of continued AFP surveillance in high-income countries has been highlighted by epidemics of a newly-recognised syndrome, acute flaccid myelitis (AFM) in the United States of America (USA) and Europe since 2014.^{3–5} AFM is a form of AFP characterised by a ‘polio-like’ pattern of spinal cord inflammation primarily affecting the central grey matter and anterior horns of the spinal cord.⁴ While cases that fit this pattern of disease have been described prior to 2014, AFM has only been recognised in the literature as an unique

syndrome since the first clusters of disease in California, USA that year.^{3,4} Since then, there is growing evidence of a causal link between AFM and outbreaks of non-polio enterovirus species, in particular enterovirus D68 (EV-D68).^{6,7} No clusters of AFM have been reported in Australia to date.

A retrospective analysis of AFP surveillance data, collected across the five tertiary referral hospitals making up the PAEDS network² between 2007 and 2017, identified increased reporting of AFP cases in early 2016, classified by the Australian Government Department of Health Polio Expert Panel (PEP) as transverse myelitis (TM) or anterior horn cell disease (AHCD). EV-D68 was detected by VIDRL in a stool sample from one case from Victoria in this cluster, referred on 1 April 2016. Here, we review AFP cases identified within the 12 months before and after this EV-D68 detection, comparing their clinical and radiological features with published diagnostic criteria for AFM.

Box 1. Acute Flaccid Paralysis and Acute Flaccid Myelitis surveillance case definitions

World Health Organization AFP surveillance definition:¹⁸

A child < 15 years of age presenting with recent or sudden onset of floppy paralysis or muscle weakness due to any cause

Centers for Disease Control and Prevention AFM surveillance definition:⁷

Clinical: An illness with sudden onset of flaccid limb weakness

Radiological: MRI showing a spinal cord lesion largely restricted to grey matter or anterior horns which spanned multiple spinal segments (may not be present on initial MRI, a negative or normal MRI performed within the first 72 hours after the onset of limb weakness does not rule out AFM). Terms in the spinal cord MRI report such as “affecting mostly grey matter,” “affecting the anterior horn or anterior horn cells,” “affecting the central cord,” “anterior myelitis,” or “poliomyelitis” would all be consistent with this terminology

CSF: Pleocytosis (WCC > 5 cells/mm³)

Confirmed AFM = Clinically compatible + MRI changes
Probable AFM = Clinically compatible + CSF pleocytosis

Abbreviations: AFP=Acute flaccid paralysis; AFM=Acute flaccid myelitis; WCC=White cell count

Methods

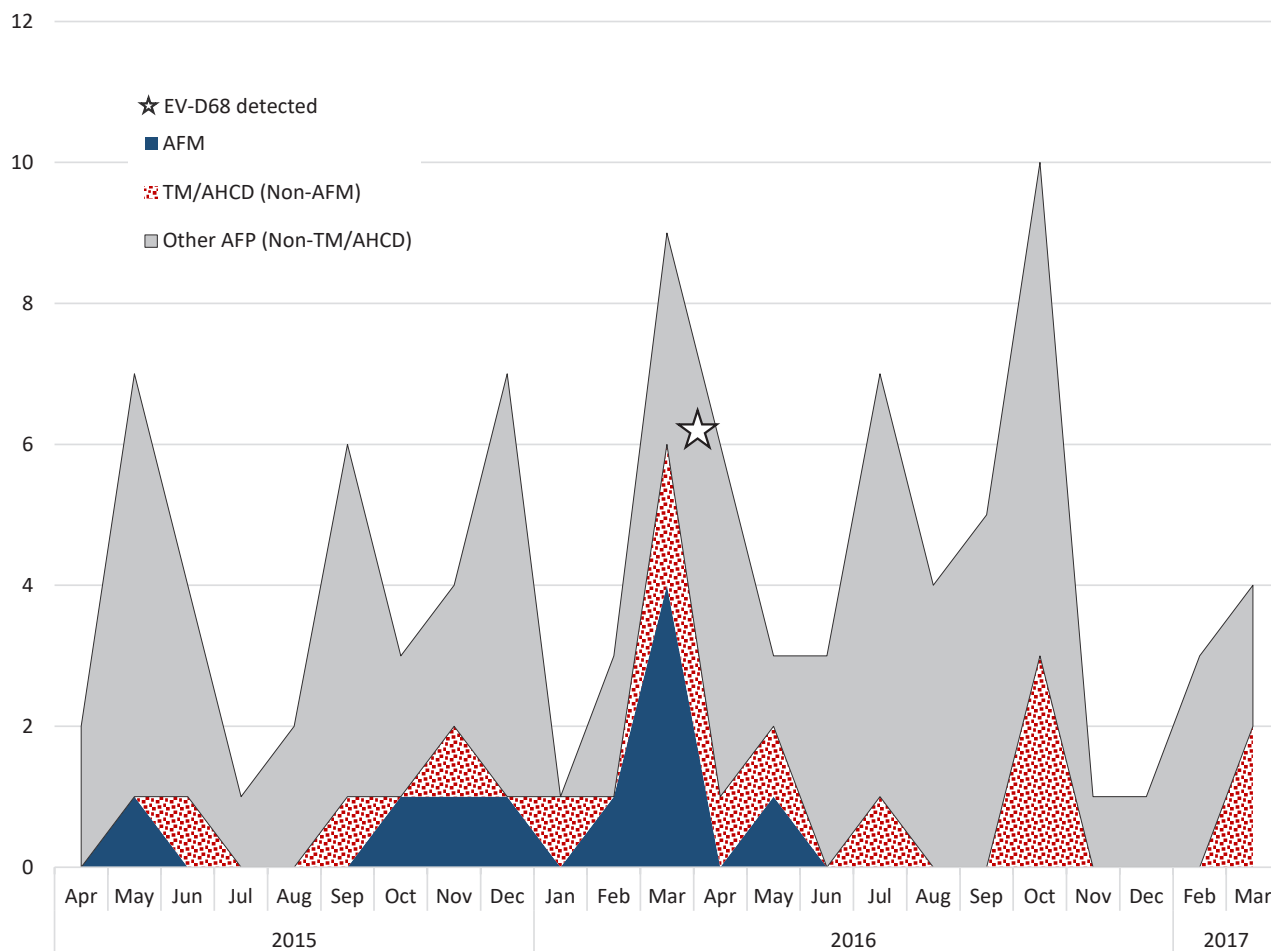
We reviewed PAEDS AFP case data collected from April 2015 to March 2017 to identify cases with a PEP classification of TM or AHCD, as these diagnoses are potentially consistent with AFM. We then reviewed spinal MRI results (collected as part of surveillance) against diagnostic criteria for AFM from the USA Centers for Disease Control and Prevention (CDC; Box 1).⁸ We recorded demographic data, site of paralysis, cerebrospinal fluid (CSF) microscopy and any potential causative agents identified from microbiological specimens. Ethics approval for PAEDS AFP surveillance was provided by the Sydney Children’s Hospital Network Human Research Ethics Committee (approval numbers 2007/009 and HREC/13/SCHN/402). Data access for this study was approved as an amendment.

Results

Between April 2015 and March 2017, hospitals in the PAEDS network identified 97 cases of AFP, of which 24 were classified as TM or AHCD. Of these 24 cases, all had spinal MRI performed and 10/24 (42%) had features satisfying radiological criteria for AFM. An additional case had suspicious, but non-definitive, MRI findings but as the PEP classified this case as AHCD we considered it AFM-compatible. AFP, TM/AHCD and AFM case counts peaked in March 2016; this temporal clustering is shown in Figure 1.

Amongst the 11 AFM cases, 4 were from Queensland, 3 from Victoria, 2 from New South Wales, and 2 from South Australia, nine (82%) were male and the median age was 10 years (IQR: 2.7; 11.7). Paralysis occurred in a single upper limb in six (55%), the rest having either bilateral lower limb (n=3) or global (upper, lower and trunk; n=2) weakness. Most cases (9; 82%)

Figure 1. Area graph showing combined monthly case counts of transverse myelitis (TM) and anterior horn cell disease (AHCD) and the proportion of these fulfilling diagnostic criteria for acute flaccid myelitis (AFM), compared to total acute flaccid paralysis (AFP) as captured by the Paediatric Active Enhanced Disease Surveillance Network between April, 2015 and March, 2017.



Abbreviations:

AFP=Acute flaccid paralysis; TM=Transverse myelitis; AHCD=Anterior horn cell disease; AFM= Acute flaccid myelitis compatible.

involved the cervical spinal cord. At discharge, nine cases (82%) had some degree of persistent weakness. Seven AFM-compatible cases showed CSF pleocytosis [median white cell count 32 cells/mm³ (IQR: 9; 57.5)]. CSF PCR testing for enterovirus was documented in five cases, all negative. Nine had at least one stool sample sent to VIDRL with EV-A71 and EV-B74 detected from one case each while the others were negative. None of the AFM-compatible cases had documented respiratory specimens submitted for viral detection at local laboratories or to VIDRL.

The single AFP case associated with EV-D68 detection occurred in April 2016 and clustered by phylogenetic analysis with EV-D68 strains reported during the 2014 USA outbreak. Although this case was classified as encephalitis by the PEP, the MRI spine scan showed ‘patchy holocord myelitis with enhancement of the anterior horn cells – grey matter’, findings that satisfy AFM criteria. Review of other AFP cases not classified by PEP as TM or AHCD revealed an additional four during the study period with MRI spine appearances compatible with AFM. All four were assigned a diagnosis of acute disseminated encephalomyelitis because

of the additional presence of MRI abnormalities on brain imaging. Only two of four had stool samples sent to VIDRL, with no enterovirus detected; no CSF or respiratory PCR specimens were documented.

Discussion

Our identification of a previously unrecognised cluster of AFM in 2015–2016 was unexpected and highlights the importance of collecting appropriate respiratory and stool specimens for viral detection in presumptive AFP cases. Identification of this cluster adds to the eight sporadic cases of AFM reported in Victorian children between 2001 and 2014.⁹ The PAEDS AFP database, including tertiary referral paediatric hospitals in five states since 2007, captures reports of MRI spine from all identified cases.² From the database, we could establish that findings compatible with AFM were rare prior to 2015–2016, with none recorded prior to 2012, and only sporadic cases reported through 2013–2014 (data not shown). However, a peak in AHCD and TM cases was also observed in late 2013, coinciding with a well-documented EV-A71 outbreak in Sydney.¹⁰ Some of these had AFM-compatible MRIs, though rarely involving the cervical spine.¹¹ Conversely, the demographic and clinical features of our 2015–2016 cluster are very similar to those of the AFM outbreak described across the USA in 2014: MRI with predominant cervical spinal cord involvement, upper limb paralysis, CSF pleocytosis, strong male predominance, and peak occurrence during summer.⁴ Now, with recognition of biannual peaks in AFM cases in the USA and documentation of an outbreak of AFM in the United Kingdom (UK) in 2018, there is a growing need to characterise the epidemiology of AFM, not only an emerging disease among children, but one with global significance particularly in countries where polio has been eradicated.^{5,12,13}

The relationship between AFM and enteroviruses has been the subject of several reviews since the 2014 US AFM outbreak, which coincided with a peak in EV-D68 infection causing asthma and other respiratory illnesses.^{4,6} EV-D68

satisfies Bradford-Hill Causality Criteria for the 2014 outbreak of AFM, an association that is further strengthened by metagenomic and microbial analysis of a cluster of AFM cases in Arizona during this period.^{6,7} CDC surveillance in the USA also demonstrated increased EV-D68 detection nationwide in 2018, coinciding with increasing AFM cases.^{13,14} EV-D68 has been previously isolated in Australia, with the first report from AFP cases identified in 2010 during a retrospective review of enterovirus surveillance data.^{15,16} However, no clusters of EV-D68-associated AFM have been recognised or reported. We acknowledge that the association of EV-D68 with this AFM cluster is indirect, limited to a single patient, and that EV-A71 was detected in another AFM-compatible patient in this period. However, PCR testing for EV-D68 is rarely positive on CSF samples in AFM cases and is less frequently detected in stool than respiratory samples.^{4,5} USA and UK AFM surveillance emphasises the importance of respiratory sampling for detecting EV-D68. In Australia, collection of stools and sub-type testing of all enteroviruses by the reference laboratory at VIDRL is recommended for all AFP cases, in accordance with WHO requirements. Referral of respiratory samples is not part of routine AFP surveillance, and virologic testing in referring hospitals is reported inconsistently in surveillance data.

We also acknowledge that this study was limited by its retrospective nature and inconsistent documentation of investigation results in the PAEDS dataset. We included only ‘confirmed’ cases of AFM with radiological features, not ‘probable’ cases with CSF pleocytosis alone.⁸ We believe that our use of highly specific criteria for classifying cases supports our contention that we have identified a genuine cluster of AFM.

In light of the emerging significance of AFM, we are working to ensure cases of AFM are prospectively sub-categorised by the PEP in order to monitor AFM in Australia. Furthermore, we emphasise to clinicians that when acute limb paralysis is identified in a child, early notification to PAEDS or APSU is important, as is

timely MRI spine imaging and collection of respiratory and stool specimens to detect enterovirus. Collection of CSF is also required, despite its poor sensitivity for enteroviruses, due to its clinical utility in other infectious and inflammatory diseases. Where enterovirus is detected from cases of AFP, we advocate sub-typing. Expanded diagnostic sampling from AFP cases will lead to clearer and more timely identification of any link between AFM and neurotropic non-polio enteroviruses in Australia and add to international efforts to describe the epidemiology and measure disease burden in the context of vaccine candidates.¹⁷

Acknowledgements

The authors would like to thank the Paediatric Active Enhanced Disease Surveillance (PAEDS) network investigators (Professor Kristine Macartney, Associate Professor Nick Wood, Professor Robert Booy, Dr Helen Quinn, Associate Professor Nigel Crawford, Dr Daryl Cheng, Professor Peter Richmond, Associate Professor Christopher Blyth, Dr Tom Snelling, Associate Professor Helen Marshall, Associate Professor Julia Clark, Dr Anne Kynaston, Dr Adam Irwin, Dr Joshua Francis, Associate Professor Jim Buttery) and the PAEDS nurses (Gemma Saravanos, Laura Rost, Kathy Meredith, Alissa McMinn, Donna Lee, Jennifer Kent, Cazz Finucane, Chris Heath, Mary Walker, Sonia Dougherty, Sara Cook, Natasha Doran, Laura Francis, Karen Bellamy), with a special note of thanks to the nurse managers Jocelyne McRae and Nicole Dinsmore. We would also acknowledge the work of the Commonwealth Department of Health Polio Expert Panel.

Author details

Dr Junchao Bao,^{1,2} General Paediatrician, The Children's Hospital at Westmead

A/Prof Bruce Thorley,³ Head of the National Enterovirus Reference Laboratory, Victorian Infectious Diseases Reference Laboratory, the Peter Doherty Institute for Infection and Immunity

Prof Elizabeth J Elliott,^{1,2,4} University of Sydney, Professor of Paediatrics and Child Health and Director, Australian Paediatric Surveillance Unit, Kid's Research, Westmead

Prof Peter McIntyre,^{2,5,6} Senior Professorial Fellow, National Centre for Immunisation Research and Surveillance, Kid's Research, Westmead

Dr Philip N Britton,^{1,2} University of Sydney, Paediatric Infectious Diseases Physician, The Children's Hospital at Westmead

1. Discipline of Child and Adolescent Health, University of Sydney, NSW
2. The Children's Hospital at Westmead, NSW
3. National Enterovirus Reference Laboratory, the Peter Doherty Institute for Infection and Immunity, Victoria
4. University of Sydney Faculty of Medicine and Health and Discipline of Child and Adolescent Health and Australian Paediatric Surveillance Unit, Kid's Research, Westmead, NSW
5. National Centre for Immunisation Research and Surveillance, Kid's Research, Westmead, NSW
6. Department of Women's and Children's Health, University of Otago, Dunedin New Zealand

Corresponding author

Dr Junchao Bao
c/o Department of General Medicine
The Children's Hospital at Westmead
Locked Bag 4001, Westmead
NSW Australia 2145
Email: junchao.bao@health.nsw.gov.au
Ph: +61 2 9845 0000 (via switchboard)
Fax: +61 2 9845 0074

References

1. Morris A, Elliott EJ, D'Souza RM, Antony J, Kennett M, Longbottom H. Acute flaccid paralysis in Australian children. *J Paediatr Child Health*. 2003;39(1):22–6.
2. (a) Paediatric Active Enhanced Disease Surveillance (PAEDS). Surveillance & Research. [Internet.] National Centre for Immunisation Research and Surveillance (NCIRS), PAEDS. [Accessed 30 May 2019.] Available from: <http://www.paeds.edu.au/surveillance-and-research/>. (b) PAEDS. About us. [Internet.] NCIRS, PAEDS. [Accessed 30 May 2019.] Available from: <http://www.paeds.edu.au/about-us/>.
3. Ayscue P, Van Haren K, Sheriff H, Waubant E, Waldron P, Yagi S et al. Acute flaccid paralysis with anterior myelitis – California, June 2012—June 2014. *MMWR Morb Mortal Wkly Rep*. 2014;63(40):903–6.
4. Messacar K, Schreiner TL, Van Haren K, Yang M, Glaser CA, Tyler KL et al. Acute flaccid myelitis: a clinical review of US Cases 2012–2015. *Ann Neurol*. 2016;80(3):326–38.
5. The United Kingdom Acute Flaccid Paralysis (AFP) Task Force. An increase in reports of acute flaccid paralysis (AFP) in the United Kingdom, 1 January 2018 – 21 January 2019: early findings. *Euro Surveill*. 2019;24(6). <https://doi.org/10.2807/1560-7917.ES.2019.24.6.1900093>
6. Bowers JR, Valentine M, Harrison V, Fofanov VY, Gillece J, Delisle J et al. Genomic analyses of acute flaccid myelitis cases among a cluster in Arizona provide further evidence of enterovirus D68 role. *MBio*. 2019;10(1). <https://doi.org/10.1128/mBio.02262-18>.
7. Messacar K, Asturias EJ, Hixon AM, Van Leer-Buter C, Niesters HGM, Tyler KL et al. Enterovirus D68 and acute flaccid myelitis – evaluating the evidence for causality. *Lancet Infect Dis*. 2018;18(8):e239–47
8. Council of State and Territorial Epidemiologists. *Standardized Case Definition for Acute Flaccid Myelitis*. <https://cdn.ymaws.com/www.cste.org/resource/resmgr/2015PS/2015PSFinal/15-ID-01.pdf>.
9. Andersen EW, Kornberg AJ, Freeman, JL, Leventer RJ, Ryan MM. Acute flaccid myelitis in childhood: a retrospective cohort study. *Eur J Neurol*. 2017;24(8):1077–83.
10. Zander A, Britton PN, Navin T, Horsley E, Tobin S, McAnulty JM. An outbreak of enterovirus 71 in metropolitan Sydney: enhanced surveillance and lessons learnt. *Med J Aust*. 2014;201(11):663–6.
11. Teoh HL, Mohammad SS, Britton PN, Kandula T, Lorentzos MS, Booy R et al. Clinical characteristics and functional motor outcomes of enterovirus 71 neurological disease in children. *JAMA Neurol*. 2016;73(30):300–7.
12. Hopkins SE, Elrick MJ, Messacar K. Acute flaccid myelitis—keys to diagnosis, questions about treatment, and future directions. *JAMA Pediatr*. 2019;172(2):117–8.
13. McKay SL, Lee AD, Lopez AS, Nix WA, Dooling KL, Keaton AA et al. Increase in acute flaccid myelitis—United States, 2018. *MMWR Morb Mortal Wkly Rep*. 2018;67(45):1273–5.
14. Kujawski SA, Midgley CM, Rha B, Lively JY, Nix WA, Curns AT et al. Enterovirus D68-associated acute respiratory illness — new vaccine surveillance network, United States, July–October, 2017 and 2018. *MMWR Morb Mortal Wkly Rep*. 2019;68(12):277–80.
15. Roberts J, Hobday L, Ibrahim A, Aitken T, Thorley B. Annual report of the Australian National Enterovirus Reference Laboratory 2012. *Commun Dis Intell Q Rep*. 2013;37(2):E97–104.
16. Levy A, Roberts J, Lang J, Tempone S, Kes-

son A, Dofai A et al. Enterovirus D68 disease and molecular epidemiology in Australia. *J Clin Virol.* 2015;69:117–21.

17. Harvala H, Broberg E, Benschop K, Berginc N, Ladhani S, Susi P et al. Recommendations for enterovirus diagnostics and characterisation within and beyond Europe. *J Clin Virol.* 2018;101:11–7.

18. World Health Organization. *Vaccine-Preventable Diseases Surveillance Standards: Poliomyelitis.* (Updated 5 September 2018.) [Accessed: 5 July 2019.] Available from: https://www.who.int/immunization/monitoring_surveillance/burden/vpd/WHO_SurveillanceVaccinePreventable_18_Polio_R2.pdf